# Clinical Outcomes Following Ayurvedic Management Of Childhood Sensorineural Hearing Loss: A Case Report

**Dr. Shraddha Chaudhary[1] , Dr. D.B. Vaghela[2]**

[1]*Ph.D. Scholar, ITRA, Jamnagar, Gujarat*
[2]*Professor, Head of Department, Shalakya Tantra, ITRA, Jamnagar*
*Corresponding author:*
*Dr. Shraddha Chaudhary, 7016419716, drsjoshi1993@gmail.com*
*ORCID: 0000-0003-2192-662*
*Submitted: 10/01/2021, Accepted: 06/12/2021, Published: 12/01/2022*

**Keywords:** Pediatric sensorineural hearing loss, Badhiryam, Ayurveda, Karnapoorana, Nasya.

**Abstract**

**Background:**
Sensorineural hearing loss (SNHL) in children can adversely affect speech development, academic achievement, and psychological well-being. Conventional management mainly includes hearing aids, cochlear implantation, and speech therapy, which primarily provide supportive rehabilitation. In ayurveda, a comparable condition is described under Badhiryam, predominantly associated with vitiation of Vata Dosha affecting the auditory pathway.

**Case Presentation:**
A 6-year old male child was brought with complaints of reduced hearing ability since early childhood, characterized by poor responsiveness to verbal commands and difficulty in understanding conversational speech. There was no significant family history of hearing impairment. Otoscopic findings were within normal limits. Auditory brainstem Response (ABR) and Audiometry testing revealed bilateral moderate to severe hearing loss. Based on Ayurvedic assessment, the condition was diagnosed as Badhiryam.

**Intervention:**
The treatment protocol included Kostha Shodhana followed by internal medications and external therapeutic procedures such as Karnapoorana and Nasya. Supportive speech therapy was advised concurrently.

**Outcome:**
Following the treatment period, the child demonstrated improved responsiveness to auditory stimuli and better speech clarity as reported by caregivers. Follow-up audiological evaluation showed stabilization and partial improvement in hearing thresholds. No adverse events were observed.

**Conclusion:**
This case suggests a potential supportive role of Ayurvedic management in pediatric SNHL. Further well-designed clinical studies are required to validate these findings.

## Introduction

Sensorineural hearing loss (SNHL) is defined as hearing impairment resulting from dysfunction of the cochlea, the eighth cranial nerve, or central auditory pathways.[1,2,3] It may be congenital or acquired and varies in severity from mild to profound. In children, SNHL is of particular concern because auditory input is essential for speech development, language acquisition, cognitive growth, and social integration.[4,5]

Delayed identification or inadequate management of hearing impairment during early childhood can lead to impaired communication skills, reduced academic performance, and psychosocial challenges. Although universal neonatal screening programs exist in many regions, hearing impairment may remain undetected until preschool or school age, particularly in resource-limited settings.

Diagnosis of SNHL requires detailed history taking and objective audiological evaluation such as pure tone audiometry (PTA), tympanometry, and Auditory Brainstem Response (ABR) testing. Management in contemporary medicine is primarily rehabilitative, including hearing aids, cochlear implants, and speech therapy.[1,4] While these approaches improve communication ability, restoration of normal cochlear function is often not achievable.

In Ayurvedic literature, hearing impairment is described under Badhiryam, which is predominantly attributed to vitiation of Vata Dosha affecting the auditory functional pathways (Shabdavaha Srotas).[6,7,8] Therapeutic strategies aim at pacifying aggravated doshas, enhancing tissue nourishment, and restoring functional balance through internal medications and procedures such as Nasya and Karnapoorana.

The present case report describes the clinical course and outcomes of a 6-year-old child with bilateral sensorineural hearing loss managed with Ayurvedic interventions and audiological follow-up.

**Case Presentation**

A 6-year-old boy was brought by his parents to the outpatient unit of Shalakya Tantra with concerns regarding diminished auditory responsiveness noted over the past few years. The parents observed that the child frequently failed to react when addressed from a distance or when called from behind. Difficulty in comprehending spoken words at normal conversational intensity was also reported.

**History**

The parents stated that the issue became increasingly noticeable after the child began interacting more socially and entering formal schooling. The child often required repetition of instructions and appeared inattentive during conversations. There was no history suggestive of chronic ear discharge, traumatic injury to the head, exposure to high-intensity sound, or intake of known ototoxic medications.

The child had experienced recurrent episodes of upper respiratory tract infections during infancy and early childhood, characterized by cough, cold, and occasional febrile illness. Despite evaluations at different healthcare facilities, no active medical treatment was initiated, and hearing amplification devices were suggested as the only option.

**Perinatal and Developmental Details**

The child was delivered at term through an uncomplicated vaginal delivery. Pregnancy and perinatal periods were uneventful. Apart from a treated episode of pneumonia during infancy, no significant neonatal complications were documented. Admission to neonatal intensive care was not required.

Immunization status was appropriate for age as per national guidelines. Developmental milestones related to motor skills were attained within expected timeframes. However, parents reported reduced clarity of speech and mild delay in expressive language compared to peers.

There was no family history of hearing impairment, congenital anomalies, or hereditary disorders.

**Clinical Evaluation and Diagnostic Assessment**

The child was examined comprehensively upon presentation. General physical assessment revealed a well-oriented and cooperative child with stable vital parameters and no systemic abnormalities. Growth and nutritional status were appropriate for age.

Otological examination demonstrated bilaterally normal external ear structures. Otoscopic evaluation revealed clear external auditory canals and intact tympanic membranes without evidence of perforation, retraction, congestion, or active discharge. Palpation over the mastoid region did not elicit tenderness or swelling.

Anterior rhinoscopic examination showed mild bilateral inferior turbinate hypertrophy without significant nasal obstruction. Oropharyngeal evaluation revealed moderate enlargement of the left palatine tonsil in the absence of acute inflammatory signs.
Objective assessment of auditory function was carried out using Auditory Brainstem Response (ABR) testing. The findings indicated elevated auditory thresholds consistent with bilateral moderate to sevre sensorineural hearing impairment. The absence of middle ear pathology on otoscopic examination, combined with ABR findings, supported a diagnosis of bilateral sensorineural hearing loss.
From an Ayurvedic standpoint, the clinical features were interpreted as Badhiryam, a condition primarily attributed to vitiation of Vata Dosha affecting the Shabdavaha Srotas (auditory functional pathway).

**Therapeutic Intervention Protocol**

**Therapeutic Intervention**
Based on the Ayurvedic diagnosis of Badhiryam with predominant Vata involvement, a combined regimen of external and internal therapies was instituted. Nasya with Anu Taila (4 drops in each nostril) was administered once daily for 7 consecutive days, followed by a 3-day interval. During each treatment sitting, Karnapoorana with Shatpushpa Taila was performed in both ears for 7 days, approximately one hour after Nasya, with a 3-day gap between cycles. This cyclical protocol was continued over a period of seven months (March 2020 – September 2020).
Internal medications included Guduchi (Tinospora cordifolia) Churna (½–1 g twice daily with honey or lukewarm water), Bala (Sida cordifolia) powder (½–1 g twice daily with honey or ghee), and Kalyanaka Ghrita (½–1 teaspoon once daily with warm milk). The internal formulations were administered throughout the treatment period with periodic clinical monitoring and dose adjustments according to digestive capacity and tolerance. Audiometric evaluation was performed at baseline and subsequently at two-month intervals to objectively assess changes in hearing thresholds during the course of therapy. No adverse effects were observed during the treatment period.

| Intervention | Formulation | Dose (Pediatric 6 yrs) | Mode of Administration | Schedule / Duration |
|---|---|---|---|---|
| **Nasya** | Anu Taila | 4 drops in each nostril | Intranasal instillation | 7 consecutive days followed by 3-day gap; repeated cyclically for 7 months (May 2022–2023) |
| **Karnapoorana** | Shatpushpa Taila | Sufficient quantity to fill external auditory canal | Oil instillation in both ears | 7 consecutive days followed by 3-day gap; performed 1 hour after Nasya during each sitting |
| **Guduchi (Tinospora cordifolia)** | Churna (Powder) / Decoction | ½–1 g twice daily | With honey or lukewarm water | Continued throughout treatment period |
| **Bala (Sida cordifolia)** | Powder (or Taila if required) | ½–1 g twice daily | With honey or ghee | Continued throughout treatment period |
| **Kalyanaka Ghrita** | Medicated Ghrita | ½–1 teaspoon (2–5 mL) once daily | With warm milk | Continued throughout treatment period |

**Follow-up**

The child was followed regularly throughout the seven-month treatment period. Clinical assessment was performed during each treatment cycle to evaluate auditory responsiveness, speech clarity, and overall tolerance to therapy. Parents were specifically asked about response to verbal commands, ability to perceive conversational speech, and changes in communicative behavior.

Objective audiological evaluation using audiometry/ABR was conducted at baseline and subsequently at two-month intervals to monitor changes in auditory thresholds. Treatment compliance was satisfactory, and no adverse events were reported during the entire course of management. Internal medications were continued under supervision, with periodic assessment of digestive capacity and general health status.

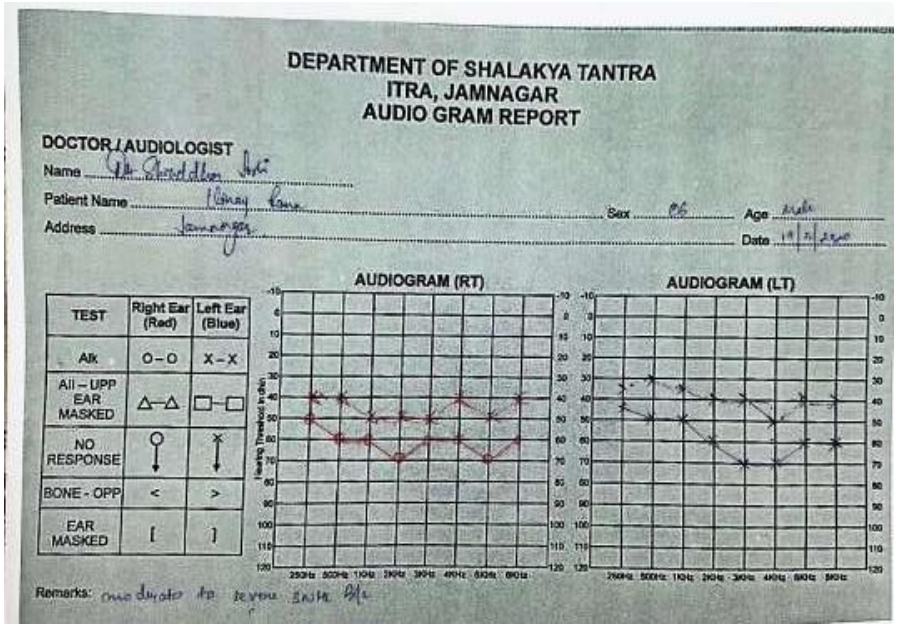


**Before Treatment**

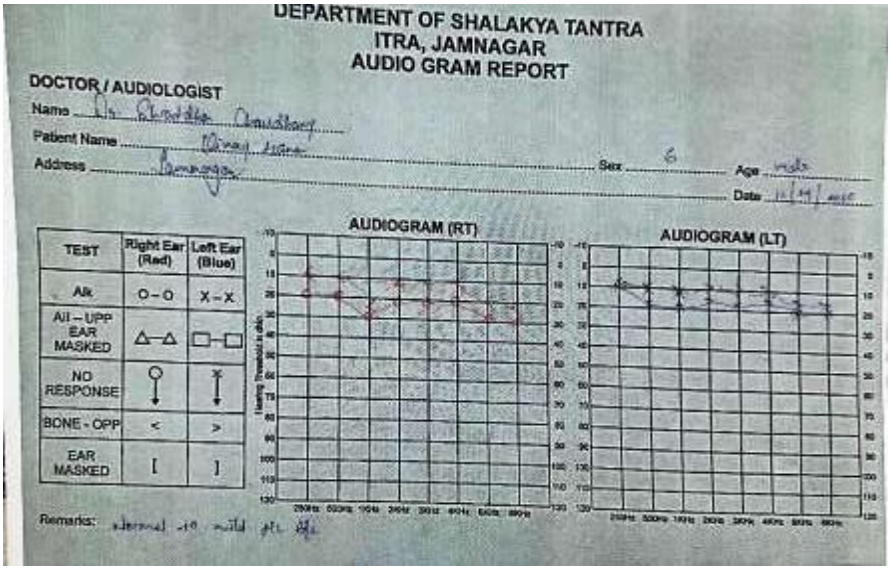


**After treatment**

**Nidana Parivarjana (Avoidance of Aggravating Factors)**
Along with therapeutic intervention, emphasis was placed on Nidana Parivarjana (elimination of causative and aggravating factors). Parents were advised to:

- Avoid exposure to loud sounds and prolonged use of electronic audio devices.
- Prevent recurrent upper respiratory tract infections through timely management of cough and cold episodes.
- Avoid excessive intake of cold, heavy, and Kapha-aggravating foods.
- Maintain proper ear hygiene without insertion of objects into the external auditory canal.
- Ensure adequate nutrition and regular daily routine to support overall development.

These measures were implemented throughout the treatment period to minimize further aggravation of the auditory dysfunction.

**Results**
At baseline, audiological assessment revealed bilateral mild-to-moderate sensorineural hearing loss. During follow-up evaluations at two-month intervals, gradual improvement in auditory thresholds was observed. Clinically, parents reported enhanced responsiveness to verbal commands, improved attention to environmental sounds, and better speech clarity over time.
By the end of seven months of therapy, repeat audiometric assessment demonstrated measurable improvement in hearing thresholds compared to baseline values (exact decibel changes to be inserted in final manuscript). No deterioration or adverse reactions were noted during the treatment course.
Overall, the combined Ayurvedic therapeutic regimen was associated with functional improvement in auditory perception and communication ability in the child.

**Discussion**
Sensorineural hearing loss (SNHL) in children represents a significant clinical challenge due to its impact on speech development, cognition, and social integration. Conventional management primarily includes amplification devices and auditory rehabilitation, with limited pharmacological options for reversing neural dysfunction. In the present case, a 6-year-old child with bilateral mild-to-moderate SNHL was managed using a multimodal Ayurvedic approach based on the diagnosis of Badhiryam.
In Ayurveda, Badhiryam is predominantly attributed to vitiation of Vata dosha affecting the auditory apparatus and the Shabdavaha Srotas.[6,7] Vata governs sensory perception and neural transmission; therefore, chronic Vata imbalance may be interpreted as functional impairment of auditory signaling. The therapeutic strategy in this case was directed toward Vata-pacification (Vata-shamana), neuro-nourishment (Brimhana), and rejuvenation (Rasayana).

**Rationale of External Therapies**

**Nasya with Anu Taila** was selected considering its classical indication in disorders of the head and neck region. Nasya is believed to facilitate drug delivery through the nasal route, which anatomically provides proximity to cranial structures.[8,9] From a contemporary perspective, intranasal administration may allow absorption through the olfactory and trigeminal pathways, potentially influencing central neural circuits. Anu Taila, being a polyherbal lipid-based preparation, possesses Vata-pacifying and neuro-supportive properties.
**Karnapoorana with Shatpushpa Taila** was administered to provide local oleation and nourishment to the auditory canal. Shatpushpa (Anethum sowa/dill) is traditionally described as Vata-Kaphahara and may aid in improving local circulation and reducing subtle inflammatory processes.[15] Although SNHL primarily involves inner ear or neural components, local oleation may help in maintaining external and middle ear health and reducing contributory factors such as recurrent infections.
The cyclic schedule (7 days therapy followed by 3-day interval) was designed to ensure sustained therapeutic exposure while preventing excessive stimulation or intolerance in a pediatric patient.

**Rationale of Internal Medications**

**Guduchi (Tinospora cordifolia)** was incorporated for its Rasayana and immunomodulatory properties. The child had a history of recurrent upper respiratory infections, which may indirectly influence middle ear function and auditory health. Guduchi is traditionally indicated for chronic inflammatory conditions and has been investigated for antioxidant and neuroprotective effects.[10,11] Its inclusion aimed to support systemic immunity and reduce recurrent inflammatory episodes.
**Bala (Sida cordifolia)** is classically described as Balya (strength-promoting) and Vata-shamaka. In neurological contexts, Bala is used for neuromuscular strengthening and functional support. Its administration in mild pediatric dosage was intended to enhance overall tissue nourishment (Dhatu poshana) and counter Vata-related functional deficits.[10,12]
**Kalyanaka Ghrita**, a medicated ghee formulation, is widely indicated in cognitive and neurodevelopmental disorders. Ghrita-based preparations are believed to facilitate delivery of lipophilic phytoconstituents across biological membranes.[7,13] From a biomedical viewpoint, ghee acts as a lipid medium that may enhance bioavailability of active compounds. The Medhya (cognitive-supporting) and Rasayana attributes of Kalyanaka Ghrita provided a rationale for its long-term use in supporting neural function and speech development.

**Critical Analysis**
It is important to acknowledge that sensorineural hearing loss, especially of congenital or early childhood onset, is often considered irreversible in conventional medicine. Therefore, complete structural regeneration cannot be conclusively inferred in this case. However, the gradual improvement in auditory thresholds and functional responsiveness observed over serial audiometric evaluations suggests possible enhancement in neural conductivity, synaptic efficiency, or reduction in subclinical inflammatory processes.
The improvement may also be partially attributed to neuroplasticity in early childhood, where timely therapeutic stimulation can optimize residual auditory function. The combined use of Nasya, local oleation, and Rasayana therapy might have synergistically contributed to functional gains.
Nonetheless, as this is a single case report, the findings cannot be generalized. Factors such as natural maturation, auditory training, environmental stimulation, or measurement variability must be considered. Controlled studies with larger sample sizes and standardized outcome measures are necessary to establish efficacy conclusively.

**Relevance of the Present Case**
This case highlights the potential integrative role of Ayurvedic management in pediatric SNHL, particularly in mild-to-moderate cases where residual hearing is present. The absence of adverse effects and the observed functional improvement suggest that such interventions may serve as supportive therapy alongside standard care.
The case also emphasizes the importance of early intervention, regular monitoring through objective audiological assessment, and adherence to Nidana Parivarjana in chronic sensory disorders.

Childhood sensorineural hearing loss poses significant challenges due to its influence on auditory perception, speech development, and psychosocial growth. The present case describes the integrative Ayurvedic management of a 6-year-old child diagnosed with bilateral mild-to-moderate sensorineural hearing loss. Based on Ayurvedic evaluation, the condition was correlated with Badhiryam characterized predominantly by Vata dosha involvement affecting the auditory functional pathway.
A multimodal therapeutic approach was adopted, combining external procedures (Nasya with Anu Taila and Karnapoorana with Shatpushpa Taila) with internal Rasayana and Vata-pacifying formulations, including Guduchi, Bala, and Kalyanaka Ghrita. The treatment was administered in a cyclic pattern over seven months with periodic clinical monitoring and objective audiometric assessment at two-month intervals.

Gradual improvement was observed both clinically, in terms of enhanced responsiveness to verbal stimuli and improved speech clarity, and objectively through serial audiometric evaluations demonstrating measurable changes in hearing thresholds. The child tolerated the treatment well, and no adverse events were reported during the course of therapy.

**Conclusion**

The present case suggests that a structured Ayurvedic therapeutic protocol aimed at Vata modulation, neuro-nourishment, and Rasayana support may contribute to functional improvement in pediatric mild-to-moderate sensorineural hearing loss. While structural regeneration cannot be conclusively established from a single case, the observed audiometric and clinical improvements indicate potential enhancement of residual auditory function.

This report highlights the possible supportive role of Ayurveda in early-stage or residual hearing impairment, particularly when instituted during the neuroplastic phase of childhood. However, given the inherent limitations of a single case study, larger controlled clinical investigations with standardized outcome measures are warranted to validate these findings and to better understand the mechanisms involved.

**Financial Support and Sponsorship**

Nil

**Conflicts of Interest**

There are no Conflict of Interest

**Reference**:

1. Cunningham LL, Tucci DL. Hearing loss in adults. N Engl J Med. 2017;377:2465–2473.
2. Hall JW. New Handbook of Auditory Evoked Responses. Boston: Pearson Education; 2007.
3. Merchant SN, Nadol JB. Schuknecht's Pathology of the Ear. 3rd ed. Shelton: PMPH USA; 2010.
4. World Health Organization. World Report on Hearing**.** Geneva: World Health Organization; 2021.
5. Nelson HD, Bougatsos C, Nygren P**.** Universal newborn hearing screening: systematic review to update the US Preventive Services Task Force recommendation**.** Pediatrics. 2008;122(1):e266–e276.
6. Acharya YT, editor. Sushruta Samhita of Sushruta with Nibandhasangraha commentary. Varanasi: Chaukhambha Sanskrit Sansthan; 2017.
7. Acharya YT, editor. Charaka Samhita of Agnivesha with Ayurveda Dipika commentary. Varanasi: Chaukhambha Sanskrit Sansthan; 2015.
8. Vagbhata. Ashtanga Hridaya with Sarvangasundara commentary. Varanasi: Chaukhambha Orientalia; 2016.
9. Shukla V, Tripathi RD. Nasya Karma: A review on therapeutic nasal administration in Ayurveda. AYU. 2011;32:453–456.
10. Sharma PV. Dravyaguna Vijnana (Vol. II). Varanasi: Chaukhambha Bharati Academy; 2011.
11. Singh N, Singh SM, Srivastava S. Neuroprotective and immunomodulatory effects of Tinospora cordifolia**.** J Ethnopharmacol. 2003;85:193–198.
12. Sharma AK, et al. Pharmacological properties of Sida cordifolia: A review. J Ethnopharmacol. 2012;144:1–12.
13. Kulkarni RR, et al. Medhya Rasayana herbs and their neuroprotective role. AYU. 2012;33:1–8.
14. Mishra S, et al. Therapeutic importance of Karnapoorana in ear disorders. International Journal of Ayurveda Research. 2013;4:176–180.
15. Merchant SN, Nadol JB. Schuknecht's Pathology of the Ear**.** 3rd ed. Shelton: PMPH USA; 2010.